

**EFFECTS OF AQUEOUS LEAF EXTRACT OF *SANSEVIERIA TRIFASCIATA* ON  
FORMALDEHYDE-INDUCED LUNG INJURY IN THE ADULT WISTER RAT**

**Authors:**

EHI-OMOSUN, Mabel Bilu and Olise, Augustina Nkechi

**Author Affiliations:**

Departments of Anatomy and Medical laboratory Science, School of Basic Medical Sciences, College of Medical Sciences, University of Benin, Nigeria.

**Correspondence:**

Dr. M.B. Ehi-Omosun,  
Department of Anatomy,  
School of Basic Medical Sciences,  
College of Medical Sciences,  
University of Benin, Nigeria.  
Email address: [mabelehiomosun@gmail.com](mailto:mabelehiomosun@gmail.com).  
Tel: +2348033551796

## ABSTRACT

Background: Formaldehyde poisoning is the most important cause of respiratory diseases among people with formaldehyde-related occupations such as laboratory scientists, nurses, medical technicians et cetera.

**Aim:** This study aimed to investigate the effects of aqueous leaf extract of *Sansevieria trifasciata* on formaldehyde-induced injury in the lungs of the adult Wistar rat.

**Methods:** The 36 adult Wistar rats weighing between 250g and 280g that were used in this research were divided into 6 groups of 6 rats per group. The haematological outcome showed that formaldehyde caused some derangements in haematological parameters especially lymphocytes and basophils, haemoglobin and haematocrit, red blood cells and their indices with associated reticulocytosis. Histologically, severe bronchiolar mucosal ulceration with erosion of the cilia leading to blunting, severe interstitial infiltrates of inflammatory cells and severe vascular ulceration were observed in the rats exposed to formaldehyde only. *Sansevieria trifasciata* shrunk the local activated immune system and the florid-activated bronchioloalveolar aggregates of the immune system in the *Sansevieria trifasciata* treated rats.

**Conclusion:** *Sansevieria trifasciata* has ameliorative effects against formaldehyde-induced injury in the lung of Wistar rats and its effect is inversely proportional to dosage. It is more potent at low doses.

**KEYWORDS:** *Sansevieria trifasciata*; formaldehyde exposure; formaldehyde poisoning

## Introduction

*Sansevieria trifasciata* is a member of the *Asparagaceae* family. It is a species of flowering plant that is cultivated in West and equatorial Africa as.<sup>[1]</sup> *Sansevieria trifasciata* is commonly called snake plant (because of the shape and sharp margins of its leaves that resemble snakes) or mother-in-law's tongue due to its sharply pointed leaves.<sup>[2]</sup> *Sansevieria trifasciata* plant has up to 6 leaves per rosette.<sup>[3]</sup> Mature leaves are dark green with light grey-green cross-banding and usually range between 30 and 35cm in length and 5 to 7cm in width.<sup>[1]</sup>

*Sansevieria trifasciata* contains the toxic alkaloid sansevesine, which has been found to also have anti-allergenic and antipyretic effects.<sup>[4]</sup> Phytochemical constituents of *Sansevieria trifasciata* include: flavonoids, saponins, phenols, steroid, coumarine, and fatty acid.<sup>[5]</sup> Literature reports that *Sansevieria trifasciata* leaves can be utilized in the therapy of fever, asthma, chest pain, cough, and catarrha. Scientists have opined that the active principles which confer antipyretic, antitussive and soothing effects on the plant are the flavonoids and its saponins.

Formaldehyde is an organic chemical reagent commonly used in disinfectants, embalming and medical laboratories.<sup>[6,7,8]</sup> Nurses, medical technicians, and laboratory scientists are often exposed to formaldehyde daily for hours during the course of their work. Breathing the fumes of formaldehyde can occur while working directly with formaldehyde, or using equipment cleaned with formaldehyde. Formaldehyde contains an organic chemical, methanol as the active ingredient which is toxic to humans with significant morbidity and mortality if left untreated.<sup>[9,10]</sup>

Previous studies have shown that exposure to formaldehyde fumes causes respiratory allergy and shortness of breath in experimental animals.<sup>[11,12]</sup> Formaldehyde vapor is a severe respiratory and skin irritant.<sup>[13,14,15]</sup> Signs and symptoms of formaldehyde poisoning include coughing, wheezing, tachypnea and inflammatory reaction.<sup>[16,17]</sup> Hence, the objective of this paper was to evaluate the effects of aqueous leaf extract of *Sansevieria trifasciata* on formaldehyde-induced damage in the lungs of adult Wistar rats.

## Materials And Method

**Plant Materials:** *Sansevieria trifasciata* leaves were harvested from the University of Benin Farm Project, Benin City. The plant was identified at the herbarium of the Department of Plant Biology and Biotechnology, Faculty of Life Sciences, University of Benin, Benin City, Edo State, Nigeria. The leaves were thoroughly washed to remove sand particles after which they were taken to the Pharmacology Department for preparation of the extract.

*Sansevieria trifasciata* leaves were chopped into little bits and allowed to dry at room temperature. The dried leaves were pounded using wooden mortar and pestle and milled into fine powder in an electric blender. Five hundred grams (500g) of the powder was soaked in 2litres of distilled water for 24 hours. The mixture was filtered with white filter paper and the residue was separated from the filtrate. The filtrate was concentrated using rotary evaporator at the department of Pharmacognosy, University of Benin, Benin City, Nigeria. The crude extract was then preserved in plain specimen bottles.

**Phytochemical Analysis:** Qualitative analysis of each Phytochemical constituent of *Sansevieria trifasciata* was done using Gas chromatography. Phytochemical constituents of *Sansevieria trifasciata* include: flavonoids, saponins, dicarboxylic acids, phenols, steroid, coumarine, homoisoflavanone and fatty acid.<sup>[5]</sup>

Acute oral toxicity of the extract was evaluated. Appropriate doses of the extract were made by diluting with distilled water into 900mg/kg body weight and 1800mg/kg body weight which were administered to the rats orally.

**Experimental Animals:** Thirty (36) adult Wistar rats of either sex weighing between 250g and 280g were used for this study. The animals were allowed to acclimatize for a period of 2 weeks before commencement of the experiment. During this period they were allowed access to standard animal feeds (Vital Growers' Feed, manufactured by Bendel Flour Mill, Ewu, Edo state Nigeria) and clean water *ad libitum*.

**Ethical Consideration:** Ethical approval was obtained from Research Ethics Committee of the College of Medical Sciences, University of Benin, Nigeria. Each animal procedure was carried out in accordance with approved protocols and in compliance with the recommendations for the proper management and utilization of laboratory animals used for research.<sup>[18]</sup>

### Induction of Formaldehyde Poisoning:

Formaldehyde poisoning was induced by exposing the test animals to 40% formaldehyde via fume distributor glass-chamber (FDC) for 1hour daily for 30 consecutive days.<sup>[16]</sup> A pilot study was done on the 28<sup>th</sup> day of the experiment which confirmed formaldehyde toxicity.

**Experimental Design:** 36 adult Wistar rats weighing between 250g and 280g were randomly assigned into a control group (**Group A**) and five treatment groups (**B, C, D, E and F**) comprising of six (6) rats per group. **Group A** rats which served as control received 1ml of distilled water daily to compensate for the stress of administration procured in the test groups. **Group B** rats were exposed to 40% formaldehyde for 1hour daily via inhalation. **Group C** rats were treated with 900mg/kg body weight per day (BWT/D) of *Sansevieria trifasciata* leaf extract. **Group D** rats were treated with 1800mg/kg BWT/D of *Sansevieria trifasciata* leaf extract. **Group E** rats were treated with 900mg/kg BWT/D of *Sansevieria trifasciata* leaf extract and were exposed to 40% formaldehyde via inhalation. **Group F** rats were treated with 1800mg/kg BWT/D of *Sansevieria trifasciata* and were exposed to 40% formaldehyde via inhalation. The dosages were given for 56 consecutive days via orogastric method. The weights of the experimental animals were taken after 30 days and the difference between them and previous weights were noted. The data were subjected to statistical analysis and P value calculated using the students' t-test.

**Method of Sacrifice and Sample Collection:** At the end of the 8<sup>th</sup> week, the animals were sacrificed under chloroform anaesthesia; a midline incision was made through the ventral wall of the thorax of the rats to access the lungs. The lungs were harvested and immediately fixed in 10% formal saline for 24 hours before the histological analysis.

The tissues were trimmed to about 3-5mm thick sections and processed according to the method of Drury and Wallington (1980)<sup>[19]</sup> And then histologically assessed using the following methods: fixation, embedding and tissue staining for microscopy. Histological sections were examined under Leica DM750 research microscope with a digital camera (Leica ICC50) attached. Photomicrographs of the tissue sections were taken at various magnifications i.e. x40 and x100.

White blood cells, lymphocytes, red blood cells, haemoglobin, haematocrit, mean corpuscular volume, mean corpuscular haemoglobin, mean corpuscular haemoglobin concentration, basophils and reticulocytes were analysed using an auto-analyzer (2006 model, manufactured by Hoddler and Stoughton Group of company, London with a recognized biochemical kit (2010 model, Diagnostic Merck, London).

**Statistical Analysis:** The results were summarized as Mean and Standard Error of Mean. The data were subjected to using the students't-test. Level of significance was set at  $P \leq 0.05$ .

**Results**

**Table 1: Change In Body Weights of the Rats in all the Experimental Groups**

<b>Groups</b>	<b>Initialbody weight</b>		<b>Final body weight</b>		<b>P-value</b>
Control (Group A)	168.00	19.90	195.00	19.22	0.158
Formaldehy. exposure only (Group B)	214.67	13.30	211.67	17.46	0.580
Extract only (low dose) (Group C)	184.00	18.04	192.00	16.70	0.062
Extract only (high dose) (Group D)	186.00	18.77	192.33	17.61	0.134
Extract (low dose) + Formaldehyde exposure (Group E)	176.67	11.86	179.67	16.75	0.605
Extract (high dose) + Formaldehyde exposure (Group F)	143.67	8.41	158.33	7.45	0.137

**Values are Mean  $\pm$  S.E.M**

**Table 2: Comparison of Haematological Parameters in all the Experimental Groups**

	(GroupA) (Control)	Group B (Formald- ehyde exposure only)	Group C Extract only (low dose)	Group D Extract only (high dose)	Group E Extract (low dose) + Formald- ehyde exposure	Group F Extract (high dose) + Formalde -hyde exposure	P- value
WBC (10 <sup>3</sup> /μL)	7.40±1.36	13.32±2.61	9.10±1.14	8.76±1.13	8.72±0.56	11.20±2.74	0.313
Lymphocytes (10 <sup>3</sup> /μL)	6.40±1.13	9.74±1.51	8.04±1.12	7.30±1.00	7.58±0.60*	9.78±2.50	0.006
Reticulocytes (%)	0.73±0.15	1.30±0.28*	0.76±0.09	1.06±0.07	0.86±0.08	0.98±0.15	0.008
Basophils (%)	9.20 ± 0.06	8.40±0.11	7.30±0.07	6.44±0.10	5.28±0.06*	4.44±0.11	0.022
RBC (10 <sup>6</sup> /μL)	5.66±0.07	5.71±0.54	5.16±0.5	5.97±0.13	6.42±0.12*	6.33±0.15	0.016
MCV(μm <sup>3</sup> )	61.53±1.07	58.42±2.11	56.04±1.44*	57.62±1.27	56.44±0.76*	56.50±0.69*	0.003
Mean Cell Haemoglobin (pg)	24.80±2.35	21.62±0.90*	20.64±0.76*	21.82 ±0.56*	21.58±0.13*	21.62±0.38*	0.002
MCHC (g/dL)	35.83±0.81	36.96±0.43	36.80±0.77	37.84±0.55*	38.32±0.38*	38.46±0.17*	0.012
Haemoglobin (g/dl)	13.33±65.86	12.40±47.12	11.80±57.48	101.80±68.74	95.80±36.73	8.40±63.61	0.006
Haematocrit (%)	43.83±0.15	42.64±0.12	41.30±0.19	40.12±0.27*	39.36±0.17	38.14±0.16*	0.004

Values are Mean ± S.E.M

\*Significantly different from the control group



PHOTOMICROGRAPHS:

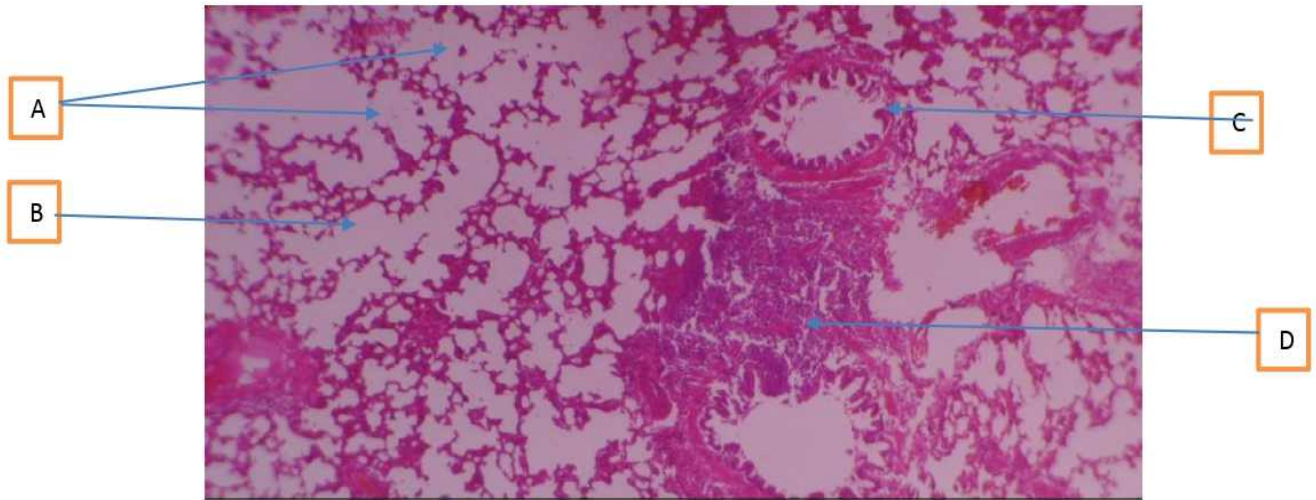


Plate 1. Lungs. Control. Composed of A: alveola sacs, B, interstitial space, C, terminal bronchiole and D, lymphoid tissue (H&E x 40)

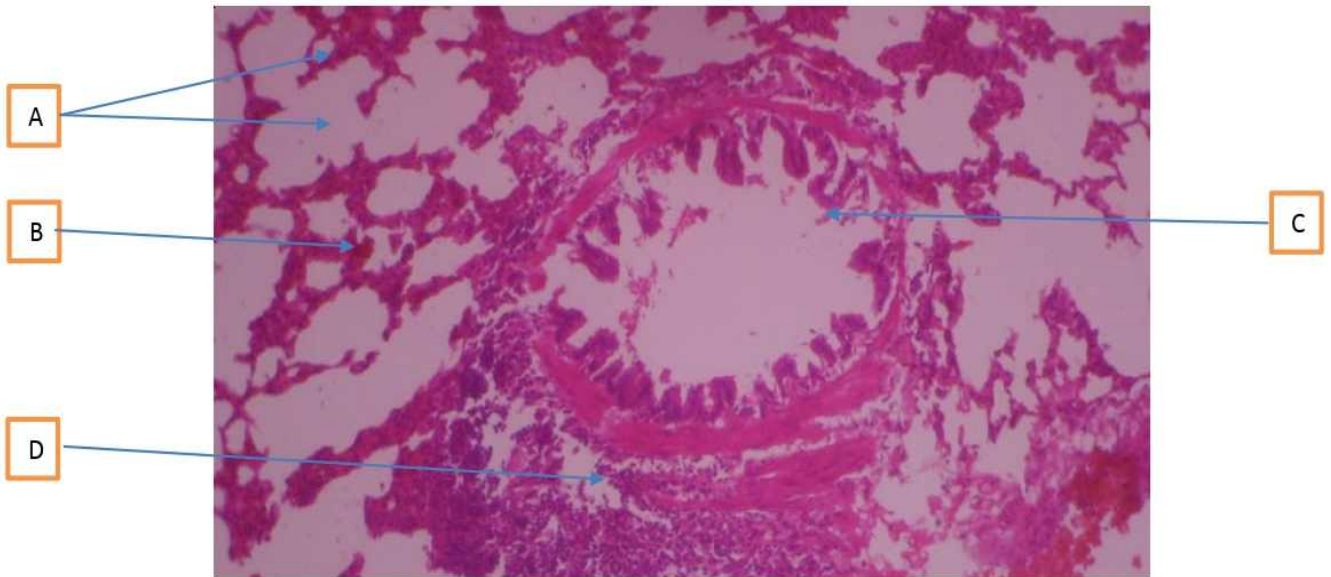


Plate 2. Higher magnification of the above: A, B, C, D (H&E x 100)

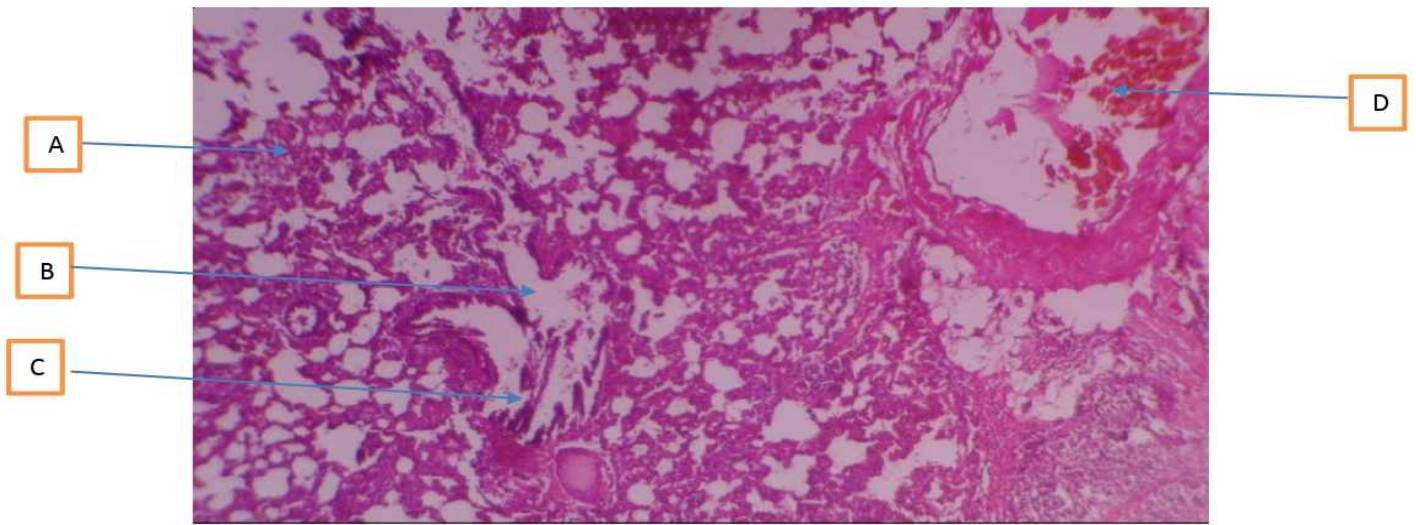


Plate 3. Rat exposed to Formaldehyde only showing A: severe interstitial infiltrates of inflammatory cells, B, bronchiolar mucosal ulceration with C, erosion of cilia and D, vascular ulceration (H&E x 40)

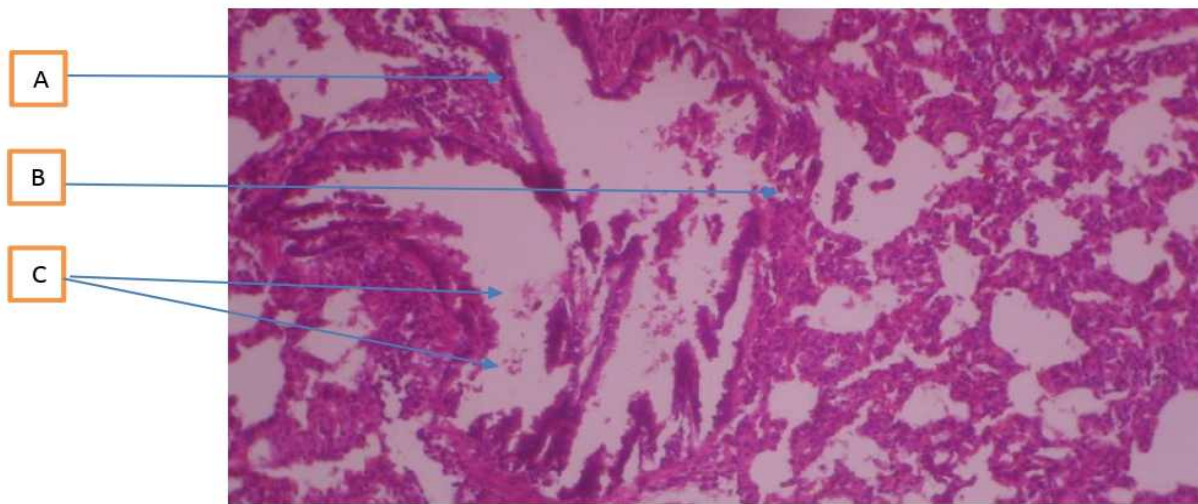


Plate 4. Higher magnification of the above: A, B, C, (H&E x 100)



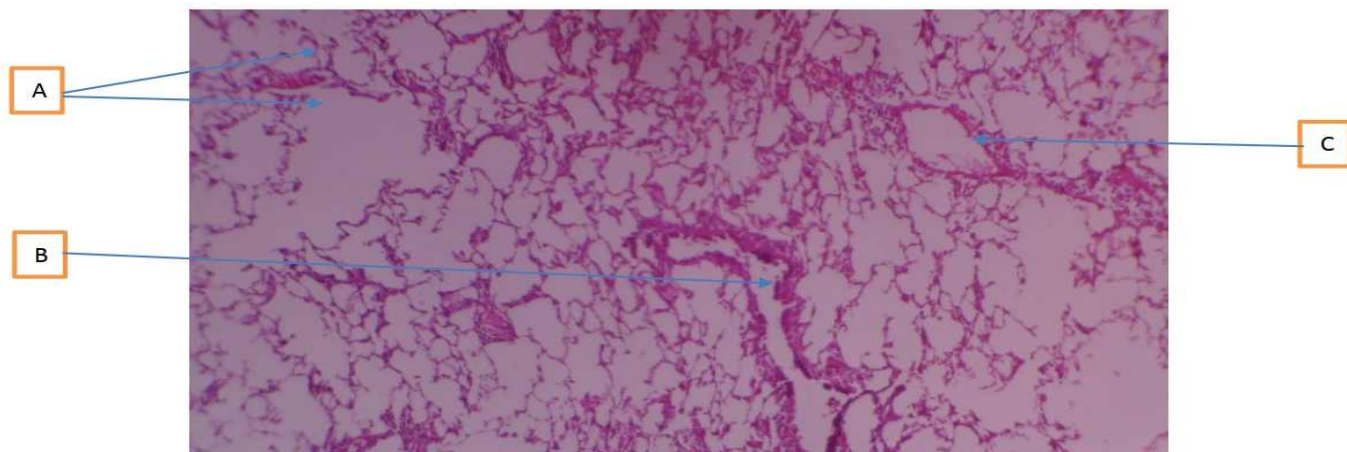


Plate 5. Rat given 900mg extract only showing A: normal alveoli, B, normal bronchiolar mucosa and C, vasodilatation (H&E x 40)

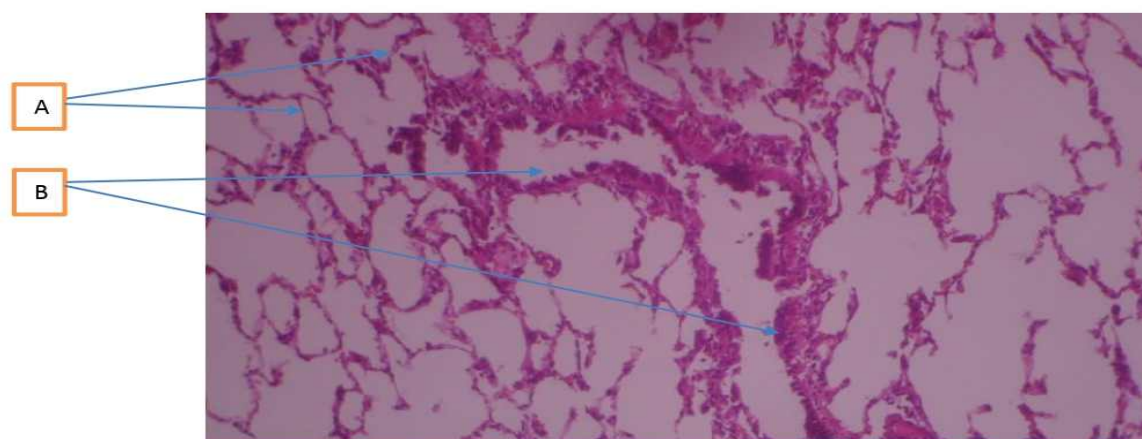


Plate 6. Higher magnification of the above: A, B, (H&E x 100)



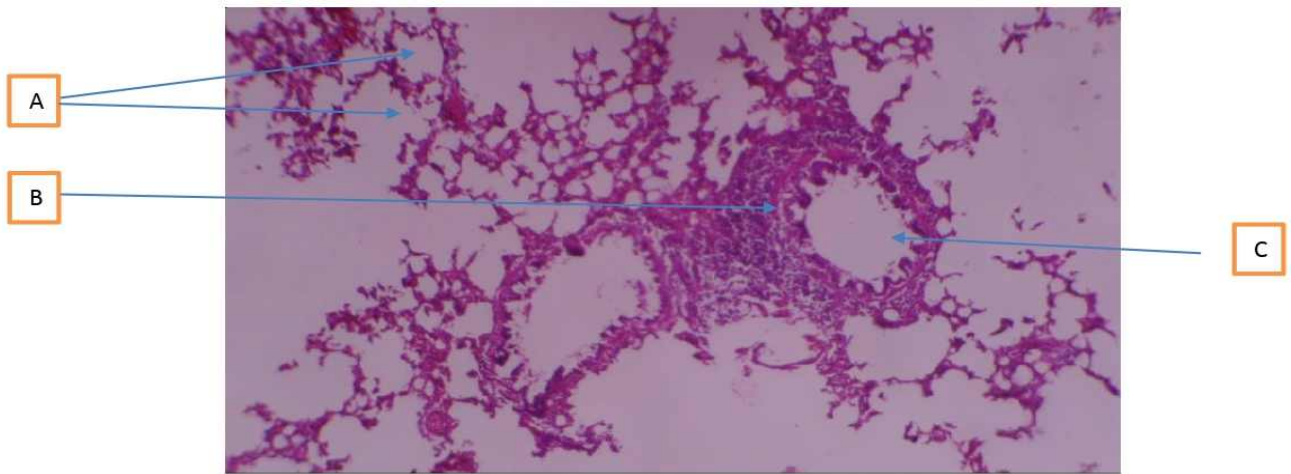


Plate 7. Rat given 1800mg Extract only showing A: normal alveoli, B, normal lymphoid tissue and C, normal bronchiolar mucosa (H&E x 40)

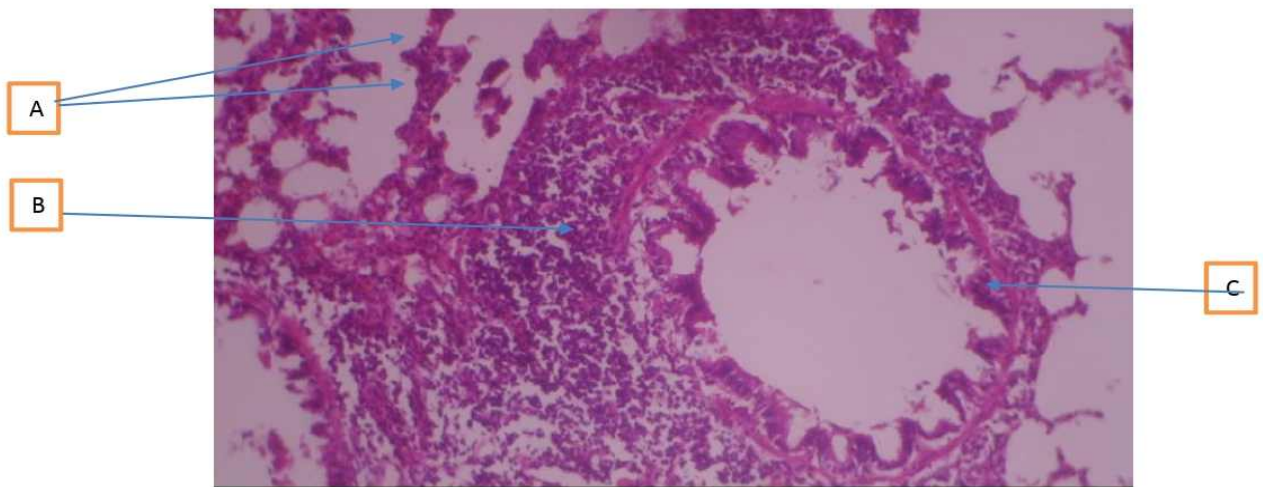


Plate 8. Higher magnification of the above: A, B, C (H&E x 100)

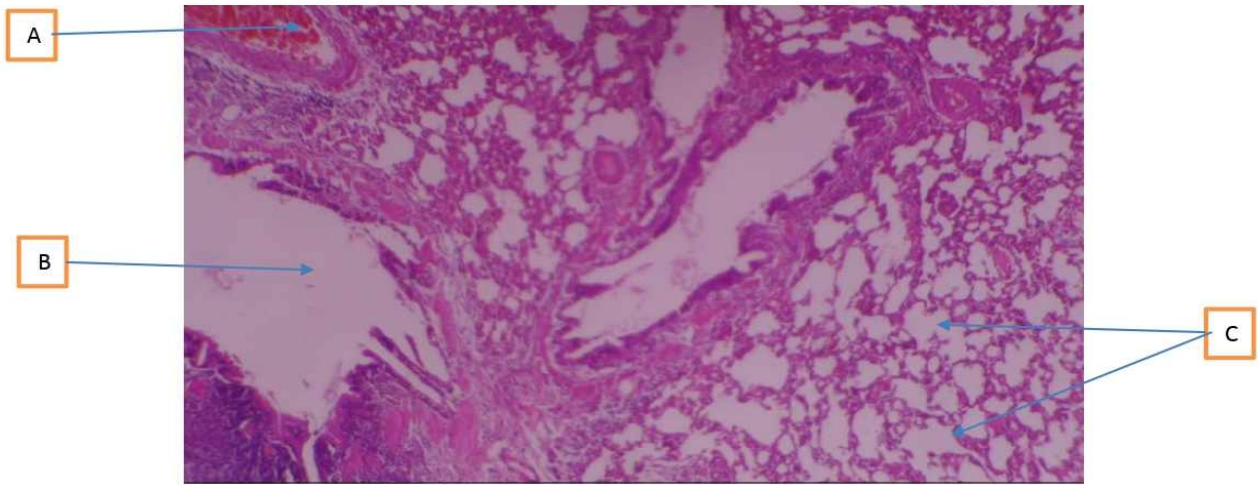


Plate 9. Rat exposed to Formaldehyde + given 900mg extract showing A: normal vascular architecture, B, bronchiolar dilation and C, normal alveoli (H&E x 40)

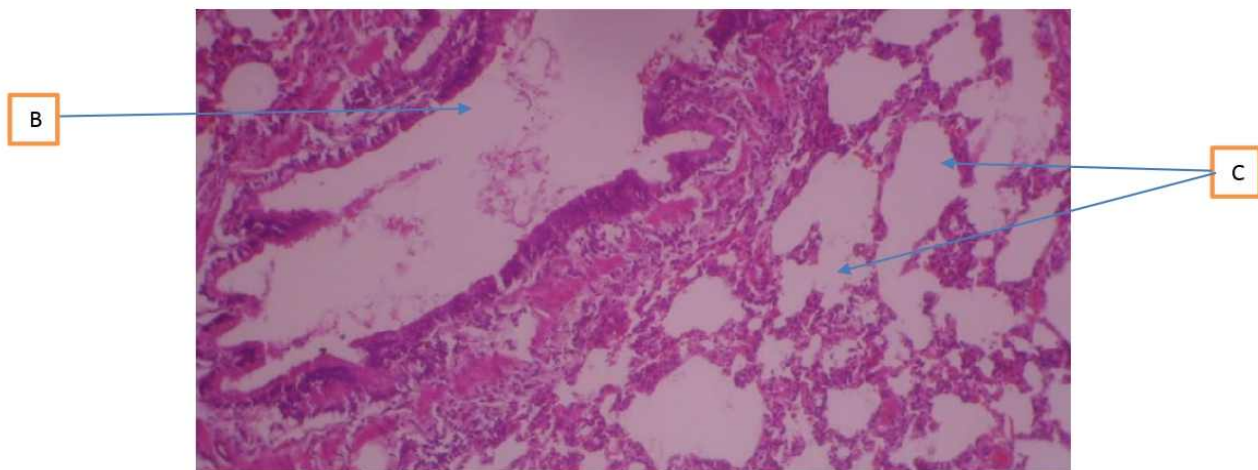


Plate 10. Higher magnification of the above: A, B, (H&E x 100)

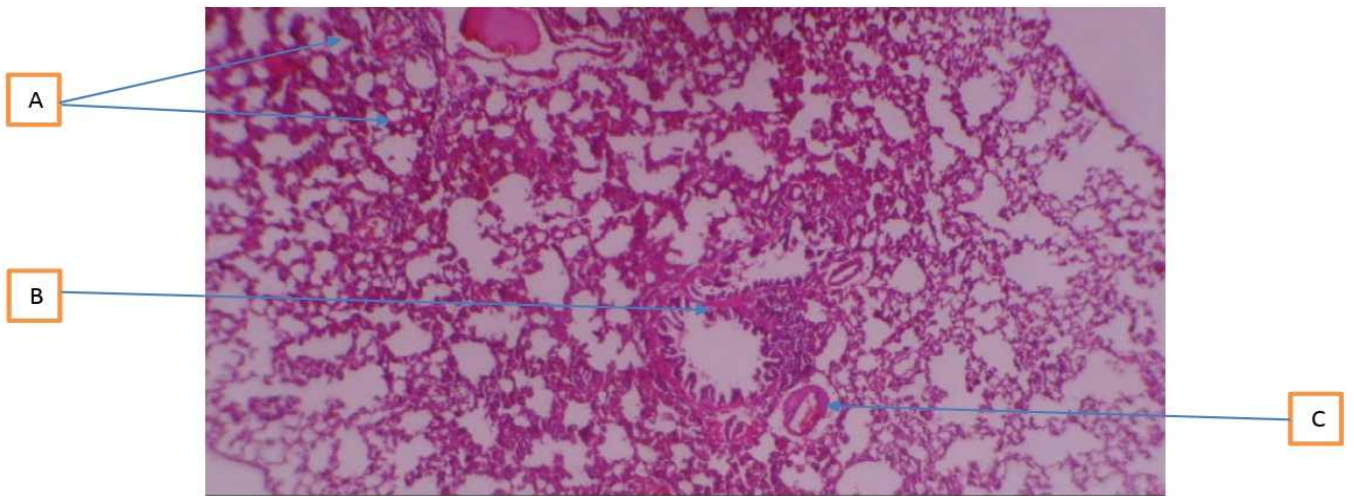


Plate 11. Rat exposed to Formaldehyde + 1800mg extract showing A: normal alveoli, B, focal bronchiolar ulceration and C, vascular ulceration (H&E x 40)

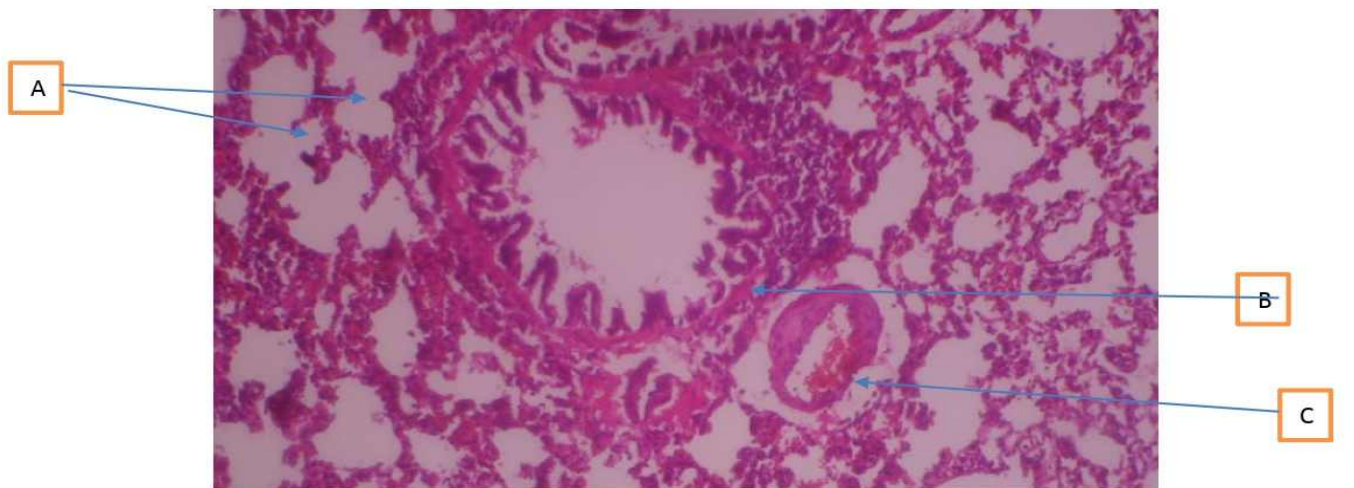


Plate 12. Higher magnification of the above: A, B, C (H&E x 100)



As shown in the table above (**Table 1**), there was no significant difference in body weight of the rats in the various groups exposed to formaldehyde (though there was a slight decrease) which concurs with previous work.<sup>[16]</sup>

As shown above in **Table 2**, haematological analysis for serum levels shows that formaldehyde decreased some hematological parameters such as lymphocytes and basophils, haemoglobin and haematocrit, red blood cells and other red cell indices with associated reticulocytosis which agrees with previous studies.<sup>[17]</sup>

As shown in **Plate 1 and 2**, the histological sections of the lung of control (**Group A**) showed normal histoarchitecture of the lung, viz., normal alveolar sacs, interstitial spaces, terminal bronchiole and lymphoid tissue. As shown in **Plate 3 and 4**, there were observable histological variations, viz., severe interstitial infiltrates of inflammatory cells, bronchiolar mucosal ulceration with erosion of cilia and vascular ulceration in the lung histoarchitecture of rats exposed to formaldehyde only (**Group B**).

As shown above in **Plate 5 and 6**, photomicrographs of lung of rats treated with 900mg/kg body weight (low dose) of *Sansevieria trifasciata* leaf extract only (**Group C**) shows normal alveoli, normal bronchiolar mucosa and vasodilatation. **Plate 7 and 8** photomicrographs of the lungs of rats treated with 1800mg/kg body weight (high dose) of *Sansevieria trifasciata* leaf extract only (**Group D**) shows normal alveoli, normal lymphoid tissue and normal bronchiolar mucosa.

As shown in **Plate 9 and 10**, histological sections of the lung of **Group E** rats exposed to 40% formaldehyde fumes and treated with 900mg/kg BWT/D of *S. trifasciata* (low dose) shows normal vascular architecture, bronchiolar dilation and normal alveoli. **Plate 11 and 12** histological sections of the lungs of **Group F** rats exposed to 40% formaldehyde fumes and treated with 1800mg/kg BWT/D of *Sansevieria trifasciata* (high dose) shows normal alveoli, focal bronchiolar ulceration and vascular ulceration.

Hematological analysis for serum levels showed that formaldehyde caused increase in the reticulocytes and decrease in some hematological parameters such as lymphocytes, basophils, haemoglobin, haematocrit, red blood cells and other red cell indices (**Table 2**). The increase in reticulocytes corresponds with the decrease in red blood cells, indicating an effective erythropoietic response.

The histological findings from this study were almost consistent throughout the lung tissue. They include inflammation of the lung interstitial space, activation of bronchial and bronchiole-alveolar lymphoid aggregates,

pulmonary oedema and focal bronchiolar ulceration. These histomorphological changes indicate diseases and pathological symptoms of a variety of maladies including bronchiolitis, alveolitis, bronchiectasis, and pneumonia. *Sansevieria trifasciata* aqueous leaf extract ameliorated all these formaldehyde-induced haematological derangements and histopathological injuries (**Fig. 9-12**).

### **Discussion**

Lymphocytes are white blood cells that are uniform in appearance but vary in function and they include T, B and natural killer cells. These cells are responsible for antibody production, direct cell mediated killing of virus-infected and tumor cells and regulation of the immune response. The lymphopenia observed in this study may have been due to the immune response to the inhaled formaldehyde fumes in the lungs as observed in the histopathological slides (Plates 3 and 4).

Basophils are a component of the granulocytes. They are fewer in number but the largest in size. They also function to defend the body against allergens, pathogens, parasites and are involved in blood clotting. The basopenia observed in this study may have resulted from the defense against the inhaled formaldehyde fumes (an allergen), which may have resulted in the depletion of their numbers. Therefore, the deranged haematological parameters observed in this study may lead to increased susceptibility to infections and anaemia in the exposed experimental animals which are capable of compromising their health and may ultimately lead to mortality.

Observations based on photomicrography show that formaldehyde caused severe interstitial infiltrates of inflammatory cells, bronchiolar mucosal ulceration with erosion of cilia and vascular ulceration (Plate 3 and 4). *Sansevieria trifasciata* had no negative effects on the histology of the lungs. Low doses of *Sansevieria trifasciata* caused an expanded lumen of the bronchioles, vasodilatation, normal bronchiolar mucosa and alveoli (Plates 5 and 6). *Sansevieria trifasciata* shrunk the local activated immune system and also the florid activated bronchio-alveolar aggregates of the immune system (Plate 9 and 10). At high doses, *Sansevieria trifasciata* showed normal alveoli, normal lymphoid tissue (Plate 7 and 8), focal bronchiolar ulceration and vascular ulceration (Plate 11 and 12) which is indicative of having a less ameliorative effect when compared to the low dose.

### **Conclusion**

*Sansevieria trifasciata* had ameliorative effects against formaldehyde-induced bronchiolar mucosal and vascular ulceration, alveolar interstitial haemorrhage, erosion of cilia and activation of lymphoid tissue. Therefore, it can be used as a substitute to combat formaldehyde poisoning and other lung diseases.



## References

1. Perez-Leon G, Chavaria-Perez L, Araya-Quesada J, Gomez-Alpizar L. Identification of the agent causing anthracnose on *Sansevieria* spp., in Costa Rica. *Agronomia Costarricense*. 2013;37(1):39-50.
2. Andhare RN, Raut M, Naik SR. Evaluation of antiallergic and anti-anaphylactic activity of ethanolic extract of *Sansevieria trifasciata* leaves (EEST) in rodents. *Ethnopharmacology*. 2012;142(3): 627-633.
3. Arnold MA. *Sansevieria trifasciata* in Landscape Plants For Texas And Environs. 3rd Ed. USA 2014; Stipes Publishers.
4. Jeba-Sunilson JA, Jayaraj P, Varatharajan R, John, T, James, J, and Muthappan M. Analgesic and Antipyretic Effects of *Sansevieria trifasciata* Leaves. *African Traditional and Complementary Alternative Medicine*. 2019;6(4): 529-533.
5. Hamidollah-Afrasiabian, Reza-Hododi, Mohammad-Hadi M, Imanieh-Alireza G, Salehi-Razak J. Phytochemical constituents of *Sansevieria trifasciata* leaf extract in Callosities of Toes'. *Global Health Science*. 2017;9:28-40
6. Moore KL, Persaud TVN. *Textbook of the Developing Human: Clinically Oriented Embryology*. 2016, sixth edition. Vanderbilt University press publishers, a Division of Harcourt Brace, Philadelphia, London.
7. Mark HB, Robert SP, Thomas VT, Justin KM, Michael BO. *The Merck manual of diagnosis and therapy*. 2006, eighteenth edition. Merck Research laboratory publishers, USA.
8. Bedino JH. *Embalming chemistry with relevant Physiology*. Second edition. Glutaraldehyde versus formaldehyde. *Expanding Encyclopedia of Mortuary Practice*. 2003;649: 2614-2632.
9. Zhang DZ, Zhang FL, Jin SY, Liu YH. Investigation on the health of workers occupationally exposed to low level of formaldehyde. *Chinese' Industrial Hygiene and Occupational Disease*. 2019;17(5): 13-14.
10. Fan W, Zhou Y, Jin F, Du L, Jin X. The health effects of pathologists exposed to formaldehyde. *Occupational Environmental Medicine*. 2016;23(6): 466-468.
11. Bach-Amedu E. One-year inhalation toxicity study of formaldehyde in male rats with a damaged or undamaged nasal mucosa. *Applied Toxicology*. 2001;8(2): 85-90
12. Hao G, Liu L, Wu J. Clinical analysis on 17 cases of acute poisoning caused by the Inhalation of formaldehyde. *Hebei Medical*. 2018;4(6): 58-69.
13. Atalanta GA. *Toxicological Profile for Formaldehyde*. 1999; Agency for Toxic Substances and Disease Registr, US Department of Health and Human Services.
14. Feng Y, Wang W, Jiang Z, Hu G, Zhong S, Zhang H. Health status of wood workers exposed to formaldehyde. *Anhui Preventive Medicine*. 1996;2(2): 99-100.
15. Aslı-Özdem O, Türkoğlu-Mustafa G, Sarsılmaz-Neriman D, Çolakoğlu-İsmail S, Tuncay-Kuloğlu A, Hıdır-Pekmez C, Ufuk-Taşo B. Formaldehyde-induced damage in lungs and effects of caffeic acid phenethyl ester a light microscopic study'. *European General Medicine*. 2008;5(3):152-156.
16. Golalipour-Shao M, Azarhoush-Alikar R, Ghafari-Ajure S, Gharravi AM, Fazeli-Davarian A. Formaldehyde exposure induces histopathological and morphometric changes in the rat testis. *Folia Morphological Studies*. 2007;66(3):167-171.
17. Costa S, Pina C, Coelho P, Costa C, Silva S, Porto B. Occupational exposure to formaldehyde. Genotoxic risk evaluation by comet assay and micronucleus test using human peripheral lymphocytes. *Toxicology and Environmental Health part A*. 2011;74: 1040-1051.
18. Buzek J, Chastel O. Directive 2010/63/EU of the European parliament and of the Council. Protection of animals used for scientific purposes (text with EEA relevance)'. *Official European Union*. 2010;34(1):276-280.
19. Drury RA, Wallington EA. *Carleton's Histological technique*. 1980 Fifth edition, Oxford University Press, New York.