

## Colorectal Cancer: A Narrative Review

Steve-nation N. Oriakhi<sup>1\*</sup>, Helen K. Odion-Obomhense<sup>1</sup>, Emmanuel Akpo<sup>1</sup>, Peter V. Orugbo<sup>2</sup>, Joyce E. Ikubor<sup>3</sup>, Obiora J. Uchendu<sup>4</sup>, Cletus I. Otene<sup>1</sup>

<sup>1</sup>Department of Surgery, Delta State University Teaching Hospital, Oghara

<sup>2</sup>Department of Chemical Pathology, Delta State University Teaching Hospital, Oghara

<sup>3</sup>Department of Radiology, Delta State University Teaching Hospital, Oghara

<sup>4</sup>Department of Histopathology and Morbid Anatomy, Faculty of Basic Clinical Science, Delta State University

Submitted: 29<sup>th</sup> Sept., 2022; Accepted: 9<sup>th</sup> Nov., 2022; Published online: 31<sup>st</sup> Dec., 2022

DOI: <https://doi.org/10.54117/jcbr.v2i6.2>

\*Corresponding Author: Steve-nation N. Oriakhi; [onenation4love@yahoo.com](mailto:onenation4love@yahoo.com); [nationoriakhi@gmail.com](mailto:nationoriakhi@gmail.com); +2348035365146

### ABSTRACT

Colorectal cancer is the second most common cancer in women and a third in men globally. Its mortality is rising with a major contribution from a low- and middle-income countries. We highlight the current trends in the demographics, histopathological patterns and management of colorectal cancer to improve care and prognosis of the disease. A search of PubMed, Hinari, Google Scholar, Directory of Open Access Journals and African Journal Online was made. Only full articles were reviewed. Most colorectal tumours develop via a multistep process involving a series of histological, morphological and genetic changes that accumulate over time. Clinical features are varied, non-specific and dependent on the site of the tumour and the extent of luminal narrowing caused by the tumour. Colonoscopy is vital in establishing the diagnosis of colorectal cancer as it allows visualization of the colon and permits tumour biopsy. Treatment is both multimodal and multidisciplinary involving surgery, radiation therapy and cytotoxic therapy. The incidence and mortality may be significantly reduced by screening which can either be invasive or non-invasive. The non-invasive uses tumour markers such as guaiac faecal occult blood test or immunohistochemical faecal occult blood test while the invasive tests include the flexible sigmoidoscopy

and colonoscopy. The burden of colorectal cancer may likely increase due to its current trend and ageing population; deficiency in cancer prevention efforts as a result of lack of government policies, low level of awareness and inadequacy of cancer registries. We advocate collaborative efforts to combat the scourge of the disease.

Running title: Colorectal cancer, a narrative review, current trends

### INTRODUCTION

There is a rising global burden of colorectal cancer, influenced by geographic location, socioeconomic status, age, and gender (Douaiher J. *et al.*, 2017). It is the third most common cancer and the second cause of cancer-related deaths globally (Globocan, 2020). Its incidence varies globally but is linked to the western lifestyle (Brenner H. *et al.*, 2014). In Africa, the disease was considered rare, but the incidence is rising dramatically, especially in the urban (Rahman G, 2010, Magaji BA *et al.*, 2017, American Cancer Society, 2020, Orugbo VP. *et al.*, 2021) . The incidence of colorectal cases in Africa rose significantly by 48% from 40,000 in 2010 to 58,000 in 2019 ( Awedew AF, Asefa Z, Belay WB, 2022). The burden in Africa is quite high and Nigeria has the highest incidence and

mortality (Figure 1). Compared with the whites, blacks have a higher early-onset colorectal cancer incidence and poorer survival (Holowaty A. *et al.*, 2020).

The causes of colorectal cancer (CRC) are multifactorial including genetic, environmental exposure, diet, and inflammatory conditions of the digestive tract. Diet plays both a causal and protective function in the development of

colorectal cancer (Thanikachalam K, 2019).

Cancer of the colorectum in West Africa occurs early and on the left side (Dakubo J et al, 2010, Irabor D et al, 2009). Most tumours are found within the lower rectum where they can be easily assessed by the examining finger. The majority of them are adenocarcinoma (Irabor D. *et al.*, 2009, Naaeder S. *et al.*, 1994, American Cancer Society, 2020).

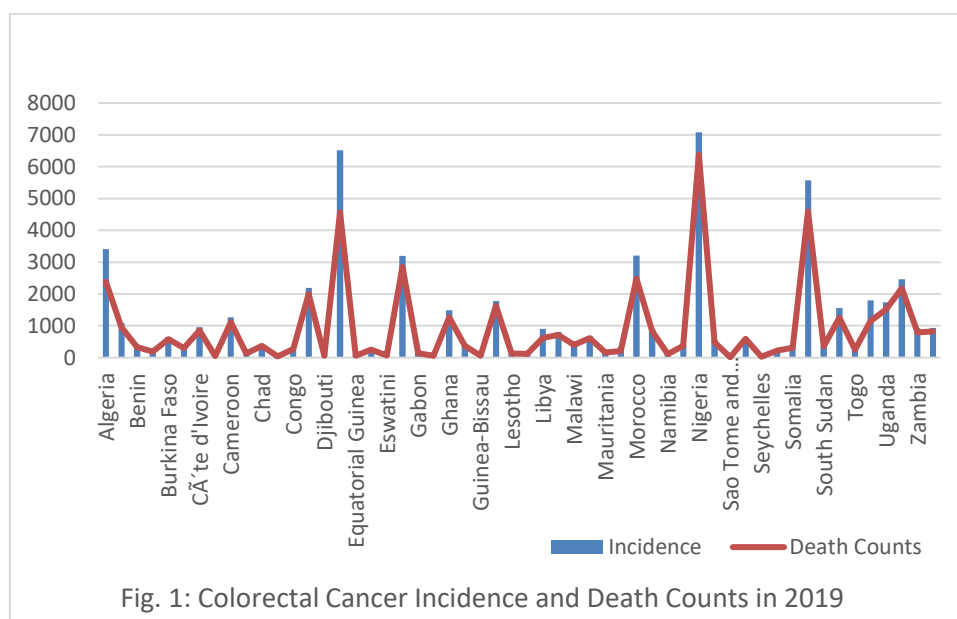


Fig. 1: Colorectal Cancer Incidence and Death Counts in 2019

\*Awedew AF, Asefa Z, Belay WB (2022)

Although the incidence and mortality rate of cancer of the colorectum has continued to decrease because of effective cancer screening measures, there has been an increase in the number of young patients diagnosed with this condition because of unclear reasons (Thanikachalam K, 2019).

The approaches to preventing CRC are grouped into three: primary, secondary, and tertiary. Primary prevention aims to reduce risk factors such as physical inactivity, alcoholism, cigarette smoking, and obesity. Secondary prevention comprises investigations such as faecal immunochemical test (FIT), flexible

sigmoidoscopy, and colonoscopy, while tertiary prevention includes the administration of low-dose aspirin and the promotion of physical activity (Brenner H et al, 2014). These measures help to reduce the incidence and mortality of colorectal cancer. Recently, a risk-adapted screening strategy using Asia-Pacific Colorectal Screening (APCS) scoring system combined with a stool DNA test has been found effective in the early detection of the risk of developing CRC (Xu J *et al.*, 2022). This approach is an effort to mitigate the complications of colonoscopy.

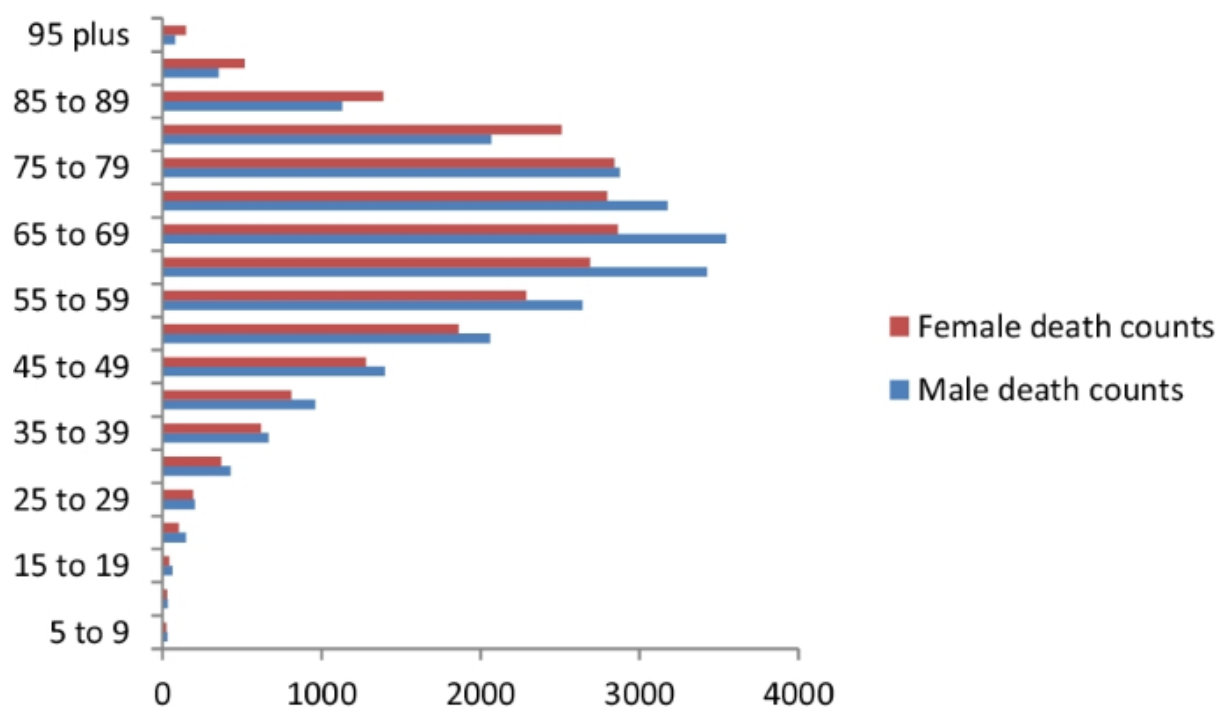
The prognosis and quality of life of patients with CRC can be substantially improved by its management, which has undergone significant evolution with recent advances in surgery, radiation therapy and targeted chemotherapy (Xie YH *et al.*, 2020).

### AETIOPATHOGENESIS

The pattern of cancer varies by location based on people's lifestyles and socioeconomic development status. The incidence of cancer of the colorectum in developing countries especially in West Africa is lower compared to the developed countries because of the consumption of a fibre diet and the rarity of adenomatous polyposis syndromes (Irabor DO, 2011). Across Africa, the peak incidence is 60 – 69 years for both males and females and the average annual incidence of CRC in Nigeria is 12.2 to 24 patients per annum and Nigerians with early-onset CRC are eight times more likely to be diagnosed with rectal cancer and at a younger age than their counterparts young African Americans (Irabor DO et al, 2014, Holowatyl A *et al.*, 2020, Theyra-Enas H. *et al.*, 2020). Earlier reports from Nigeria showed an equal male-to-female ratio and a peak age of 41- 44 years, although there is a significant subgroup of the under-30s (Irabor D *et al.*, 2009, Theyra-Enas H. *et al.*, 2020). Colon cancers are less than rectal cancers with the

caecum being the favoured site (Irabor D *et al.*, 2009). More recent reports show a male preponderance with a male-female ratio of 1.3:1 (Theyra-Enas H. *et al.*, (2020). The rectum remains the most common site of colorectal cancer in a ratio of 2.5:1 followed by the left colon (Theyra-Enas H. *et al.*, 2020, Irabor DO, 2014). It is more common among urban dwellers and public/civil servants are the most affected (Theyra-Enas H. *et al.*, 2020). The predominant histological type is the adenocarcinoma with 62-89.5% being well differentiated, 2.3-33% of the mucinous variety, 1.9-5.5% signet ring while 2.3-19.4% were anaplastic types (Irabor D et al, 2009, Theyra-Enas H. *et al.*, 2020). Mucinous cancer has a bad prognosis and is common in younger patients (Irabor D. *et al.*, 2009). Reports from 54 African countries on the death count from CRC show that age specific death counts peaks at 60 – 69 years for males and 65 – 79 years for females (Figure 2) (Awedew AF. *Et al.*, 2022).

Colorectal cancer begins as a benign tumour that grows into adenocarcinoma through a sequence of histological progression from either adenomas or hyperplastic polyps/serrated adenomas. Approximately 50% are linked to diet and about 15-20% to genetic factors (Butterworth JR. *et al.*, 2006).



## RISK FACTORS

Colorectal cancer can develop in any individual but modifiable and non-modifiable factors account for a rise in the disease incidence. Modifiable risk factors include diet, obesity, lack of physical activity, and tobacco and alcohol use (Hagggar FA. *et al.*, 2009). Although increased consumption of dietary fibre, green leafy vegetables, folate, and calcium have been reported to be protective against the formation of cancer of the colorectum (Simon K. *et al.*, 2016, American Cancer Society, 2015).

The non-modifiable risk factors include previous history of polyps or cancer of the colorectum, hereditary conditions such as Lynch syndrome, a personal history of inflammatory bowel disease, racial and ethnic backgrounds, and the presence of type 2 diabetes (Simon K *et al*, 2016, American Cancer Society, 2015, Poullis A. *et al.*, 2004, American Cancer Society, 2011).

## DEVELOPMENT OF COLORECTAL CANCER

Most colon tumours develop via a multistep process involving a series of histological, morphological, and genetic changes that accumulate over time (Frank SA, 2007).

### Polyps:

Colorectal cancer arises from benign, precancerous polyps, which may be sessile or pedunculated. There is a genetic change in the polyps that occur after sometime where they acquire the ability to invade the bowel wall (hallmark of CRC) and eventually spread to local lymph nodes and distant metastatic sites. Luckily, only a small fragment of polyps acquire malignant features and the progression of these polyps to cancer takes several years or even decade to accomplish (American Cancer Society, 2011, Frank SA, 2007).

There are two main types of polyps with malignant potential, they are adenomas and sessile serrated polyps (SSPs), each of them has different risks of developing Colorectal cancer. Adenomas can be tubular, villous or tubulovillous, while SSPs includes hyperplastic polyps, sessile serrated

adenomas, serrated adenomas (traditional) and mixed polyps. They have all been associated with Colorectal cancer (CRC) development (Conteduca V. *et al.*, 2013, Yamane L. *et al.*, 2014).

As the size of the polyp gets bigger, likewise the risk of adenomas developing into colorectal cancer increases (Conteduca V. *et al.*, 2013). About 60% - 70% of CRCs develop from adenomas while the rest develop from Sessile serrated polyps (SSPs) also called sessile serrated adenomas (Yamane L. *et al.*, 2014, East JE. *et al.*, 2015, Snover DC. *et al.*, 2011, De Palma, 2019).

Colorectal cancer (CRC) occurs in hereditary, sporadic and familial forms.

Hereditary colorectal cancer is through Familial Adenomatous Polyposis (FAP) and Hereditary Non-Polyposis Colorectal Cancer (HNPCC) and is characterized by family history and young age at onset.

Sporadic colorectal cancer occurs in the absence of family history, affects an older population (60 to 80 years of age), and is usually manifested as an isolated colon or rectal lesion.

Genetic mutations associated with the cancer are limited to the tumour itself, unlike in hereditary disease, in which the specific mutation is present in all cells of the affected individual.

Distinct histological features of Nigerian patients with cancer of the colorectum include poor differentiation (34%), invasive growth (96%), mucinous (10%) and signet ring cell adenocarcinomas (4%) (Badmos KB. *et al.*, 2018).

## CLINICAL FEATURES

The signs and symptoms of cancer of the colorectum are varied, non-specific and dependent on the site of the tumour as well as the extent of constriction of the lumen caused by cancer.

The commonest features include alterations in bowel habits such as constipation, diarrhoea or alternating constipation and diarrhoea; abdominal pain, weight loss, passage of blood or mucus in stool, abdominal mass and anaemia.

Colonoscopy is vital in establishing the diagnosis. It allows visualization of the colon to exclude metachronous polyps or cancer and also permits a biopsy of the tumour for histological diagnosis.

The duration of presenting complaints is usually from 3 weeks to 10 years, most patients present at 7–10 months with more than one symptom (Theyra-Enas H. *et al.*, 2020). In a cohort of 122 patients, bleeding per rectum was the most common symptom seen in 20% of cases (Theyra-Enas H. *et al.*, 2020).

## IMAGING TECHNIQUES FOR THE DIAGNOSIS OF COLORECTAL CANCER

The goal of imaging in Colorectal cancer is to establish the diagnosis and stage of the disease so that the proper therapy can be instituted. Radiological diagnosis of the tumour is traditionally made using a barium enema which detects CRC in about 85% of cases, although the newer modalities of CT and CT colonography have superseded this traditional role (Kajihara Y, 2019).

Barium enema either a single contrast or a double contrast (DCBE) is the routine imaging modality of examining the colon. Contrast enema studies demonstrate the configuration and calibre of the colorectum. It can diagnose lesions and provide information on the extent of involvement of the lesions in the colon. In addition, DCBE is the best imaging modality of the colon, for it has the inherent advantage of demonstrating the fine mucosal detail of the colorectum. It also has a valuable role among other screening tools for CRC

(Glick S, 2000). A major disadvantage of the contrast enema examination is the patient preparation which requires bowel preparation. In addition; children, the elderly, critically ill and weak patients are unable to tolerate the rigours associated with the technique of DCBE. These disadvantages of the contrast enema make the use of computed tomography advantageous over it.

DCBE is the initial imaging investigation of choice in detecting CRC (Mensah YB. *et al.*, 2011, Connolly DJA. *et al.*, 2002). Radiologically, on DCBE examinations, CRC may present as an annular filling defect with irregular and shouldered margins giving the appearance of the “apple-core” which is classic for CRC. There is also a loss of mucosal detail (Kajihara Y, 2019).

Missed diagnosis CRC with DCBE is an issue of concern as there is an approximately one in five probability that a CRC can be missed following DCBE (Toma J. *et al.*, 2008). Cancers that are less than 3cm in length and do not have circumferential involvement were more likely to be missed (Tan KY. *et al.*, 2004). Missed rate of diagnosis and perceptive errors of diagnosis CRC with DCBE has been reduced by double reporting (Leslie A. *et al.*, 2002).

The use of abdominal CT and CT colonography (CTC) is currently in favour over the barium enema which is now being gradually replaced by these newer imaging modalities as these two have higher sensitivity in detecting CRC (Halligan S. *et al.*, 2005, Shariff MK. *et al.*, 2011).

Abdominal CT and CT colonography have been reported to have higher sensitivity and better tolerance in the identification of CRC over barium enema (Halligan S. *et al.*, 2005, Shariff MK. *et al.*, 2011, Yee J. *et al.*, 2001).

The advent and increased practice of colonoscopy has overtaken the role of

contrast enema in the identification of CRC. In addition, it has the superior advantages of its interventional capability of biopsy and in some cases, instituting treatment. However, in clinical scenarios where colonoscopy is incomplete or inconclusive, DCBE has to be relied upon for the diagnosis (Neri E. *et al.*, 2002, Chong A. *et al.*, 2002). Furthermore, because DCBE and CT are dynamic studies done in real-time, they can be recorded. They have the advantage of documentation over colonoscopy (Rex DK, 2016). Barium enema examination has a diagnostic yield of 3.2% for cancerous lesions greater than 1 cm that was not visualized in the colon after an incomplete colonoscopy (Neri E. *et al.*, 2002).

## TREATMENT

Treatment of colorectal cancer depends on complete and accurate histopathology reporting of colorectal carcinoma (CRC) resection specimens (Butterworth JR, 2006).

Colorectal cancer can present as either obstructing or non-obstructing tumours but the aim of treatment is curative resection.

Patients with non-obstructing tumours undergo a variety of surgical interventions such as right hemicolectomy, left hemicolectomy, anterior resection, abdominoperineal excision of the rectum and colostomy alone in some cases (Irabor D, 2009). While patients with complete obstruction will undergo emergency resection of the segment of the colon containing obstructing cancer, thereafter an end-to-end anastomosis (as one stage procedure) can be done or suture closure of the distal segment and construction of a temporary colostomy (Hartmann operation).

**RADIATION THERAPY:** these are beneficial to patients that have colorectal cancer (most especially rectal cancer) and

can be given either preoperatively or postoperatively.

Preoperative radiation is superior to post-operative radiation. When combined with chemotherapy is used for locally advanced distal rectal cancers.

**CYTOTOXIC THERAPY:** Patients with stage III or high-risk stage II improve significantly from chemotherapy. The chemotherapeutic agent used for treatments includes 5-fluorouracil, capecitabine, irinotecan, oxaliplatin and cisplatin.

### SCREENING

Screening and detection of early-stage precancerous polyps in individuals at risk of cancer of the colorectum before turning cancerous may lead to significant decreases in CRC incidence and mortality (Simon K. *et al.*, 2016).

Its effectiveness is affected by factors such as limitations of test performance, lack of accessibility and suboptimal screening compliance (Issa IA. *et al.*, 2017).

The ideal screening test should have high sensitivity and specificity, and be safe, available, convenient and cheap (Issa IA. *et al.*, 2017). The methods are divided into invasive and non-invasive tests.

The non-invasive tests involve the use of tumour markers which are biochemical substances (biomarkers) in plasma and other body fluids (such as cerebrospinal fluid, urine etc) as well as body tissues that can be measured and evaluated as an indicator of normal biologic/ pathogenic processes or pharmacologic responses to therapeutic intervention, monitoring of therapy or in evaluating prognosis (Dilley J. *et al.*, 2014). These substances are often produced by tumour cells or healthy cells in response to tumours. The markers aid in screening tests, differential diagnosis, prognosis and in disease progress or regression monitoring. It can also help in differentiating benign from malignant tumours and also assist in diagnosis in

situations of unspecific histological morphologies (Hemming AW. *et al.*, 1992).

Molecular diagnostic methods in CRC diagnosis are more based on the use of non-enzymatic tumour markers. Substances used in CRC diagnosis and management include guaiac faecal occult blood test (gFOBT). It is usually the most commonly used. It is cheap, non-invasive and used as a screening and diagnostic procedure for CRC. The test is based on haemoglobin presence in faeces, indicating bleeding from the gastrointestinal tract. The limitation is that blood in faeces is a non-specific indicator of CRC because it may come from non-cancerous tumours like polyps (Mead R. *et al.*, 2011).

There is a second occult blood test using an immunochemical technique. This is the immunohistochemical faecal occult blood test (FIT). This test is based on human globin, the protein building block of haemoglobin (Ebell MH. *et al.*, 2018).

CA 19-9 is a carbohydrate antigen glycoprotein tumour marker seen also in tumorous growths of the gastrointestinal tract. CA 19-9 elevations are evaluated in the diagnosis, therapy and monitoring of CRC tumours. Other carbohydrate antigens include CA 242, CA 195, CA 72-4, CA 50, CA M29 and CA M26 (Lech G. *et al.*, 2016).

### Genetic based diagnosis

Diagnosis of CRC tumours involves the use of deoxyribonucleic acid (DNA), usually in form of tumour-specific mutations of DNA called circulating tumour DNA (ctDNA) which are detected in CRC patients' plasma (Yang H. *et al.*, 2013). Other markers in the genetic basis are auto-antibodies to CRC cells called serum anti-p53 antibodies.

There are also faecal DNA markers involving p53, KRAS, tumour antigen of colorectal cancer (tumour-associated glycoprotein (TAG-72), tissue polypeptide specific antigen (TPS) and canine scent detection for volatile organic compounds.



The most reliable screening method is canine scent detection for volatile organic compounds in faeces (Deschoolmeester V. *et al.*, 2010, Newton KP. *et al.*, 2012).

Epigenetic disorders involving DNA methylation and covalent histones modifications are also being evaluated for CRC diagnosis. These show disorders in gene regulatory pathways. The regulatory pathways produce progressive changes from benign adenomas to carcinomas including p53, Wnt, DNA mismatch repair genes and Ras drive the progression of the disease from benign adenoma to carcinomas. There can be progression to metastatic disease. Some tests use reverse transcriptase polymerase chain reaction (RT-PCR) in the detection of messenger ribonucleic acid (mRNA) present in circulating tumour cells (CTCs) (Aslam MI. *et al.*, 2009, Tanaka T. *et al.*, 2010). “Epi procolon” is an in vitro diagnostic polymerase chain reaction (PCR) test for the identification of mutated methylated septin9 DNA associated with CRC (Center for Disease Control and Prevention, 2011).

The underlying pathological disorder involves genomic instability, which is pivotal to the development of CRC and progression to chromosomal instability (CIN) and microsatellite instability (MSI). Markers are usually assayed in blood, urine or faeces (Kim MS. *et al.*, 2010, Duffy MJ. *et al.*, 2007)

Invasive tests include the flexible sigmoidoscopy and colonoscopy which offer direct visualization and detection of a colonic polyp or advanced neoplasia with the advantage of obtaining a biopsy for histopathological examination (Issa IA. *et al.*, 2017). The importance of screening cannot be overemphasized as it helps to prevent cancer morbidity, mortality and the huge financial burden of metastatic cancer (Simon K. *et al.*, 2016).

## SKIN INVOLVEMENT OF COLORECTAL CANCER

Skin manifestation (metastasis) of colorectal cancer is reported to be extremely rare, usually portends poor prognosis as well as widespread disease and often appears several years after diagnosis or resection of the primary tumour (Patnayak R. *et al.*, 2018, Wang DY. *et al.*, 2017, Nessleris I. *et al.*, 2013). It accounts for 2.3% to 6.0% of cases (Zanwar VG. *et al.*, 2016).

Abdominal skin is the most frequent site of metastasis of colorectal cancer, while other common sites are the pelvis, back, chest, upper extremities, head and neck (Wang DY. *et al.*, 2017, Nessleris I. *et al.*, 2013).

Clinically these lesions appear as painless, firm nodules or purple-red indurations known as carcinoma erysipeloides (Nessleris I. *et al.*, 2013, Zanwar VG. *et al.*, 2016, Krathen RA. *et al.*, 2003). Ulceration, bullae, nodules and fibrotic processes are the most common presentations of skin metastasis (Sheets N. *et al.*, 2014).

Microscopic features of the lesion resemble those of the primary tumour (Patnayak R. *et al.*, 2018). The mechanism of cutaneous spread is not clear. Direct extension, lymphatic or haematogenous spread, spread via embryonic origin ligaments and implantation of tumour cells has been suggested (Krathen RA. *et al.*, 2003).

Surgical excision, radiotherapy, chemotherapy and targeted therapy are available treatment options, considering the poor prognosis. Treatment options depend on the type of primary tumour, the extent of the tumour and metastatic disease as well as the genetic characterization (Dong Z. *et al.*, 2015). In the case of isolated lesions, wide local excision is the preferred treatment (Patnayak R. *et al.*, 2018, Frympas G. *et al.*, 2006). Excision of extensive lesions can leave wide abdominal wall defects. For patients with multiple skin metastases or unresectable lesions, cytotoxic



chemotherapy, targeted therapy or immunotherapy could be considered (Frympas G. *et al.*, 2006).

Other treatment methods that have been considered include cryotherapy, radiotherapy, radiofrequency ablation, laser ablation, isolated limb perfusion, polychemotherapy, interferon alpha injections, imiquimod 5% cream and oncogene-targeted therapy (Wang DY. *et al.*, 2017).

Combining irinotecan and 5-FU (Fluorouracil); oxaliplatin, 5-FU and Leucovorin (LV) or 5FU, LV and irinotecan has increased survival to over 20 months (Nessleris I et al, 2013, Krathen RA. *et al.*, 2003). Overall survival after confirmation of skin metastasis ranges from 1-34 months. The median survival for patients is 18 months (Wang DY. *et al.*, 2017, Nessleris I. *et al.*, 2013, Krathen RA. *et al.*, 2003).

## CONCLUSION

The burden of colorectal cancer may likely increase over time due to its current trend and ageing population; deficiency in cancer prevention efforts as a result of lack of government policies, low levels of awareness and inadequacy of cancer registries. Hence a collaborative effort is needed to combat the scourge of the disease.

## REFERENCES

- American Cancer Society (2011). Colorectal Cancer Facts & Figures 2011-2013
- American Cancer Society (2015). Cancer Facts & Figures 2015.
- American Cancer Society (2020). Colorectal Cancer Facts & Figures 2020-2022. Retrieved on October 9, 2022, from <https://www.cancer.org/content/dam/cancer-org/research/cancer-facts-and-statistics/colorectal-cancer-facts-and-figures/colorectal-cancer-facts-and-figures-2020-2022.pdf>
- Aslam MI, Taylor K, Pringle JH, Jameson JS (2009). MicroRNAs are novel biomarkers of colorectal cancer. *Br J Surg.* 96: 702-10
- Awedew AF, Asefa Z, Belay WB (2022). Burden and trend of colorectal cancer in 54 countries of Africa 2010–2019: a systematic examination for Global Burden of Disease. *BMC Gastroenterol* 22: 204. Retrieved on October 28, 2022 from <https://doi.org/10.1186/s12876-022-02275-0>
- Badmos KB, Abdulkareem FB, Rotimi O, Lawal AO, Osinowo AO, Habeebu MY (2018). Histopathological report of colorectal carcinoma resections: A 5-year audit in Lagos. *Niger Postgrad Med J.* 25(1): 32-36.
- Brenner H, Kloor M, Pox CP (2014). Colorectal cancer. *Lancet.* 383 (9927): 1490-1502.
- Butterworth JR (2006). Another important function for an old friend! The role of iron in colorectal carcinogenesis. *Gut.* 55(10); 1384 – 1386
- Centers for Disease Control and Prevention (CDC) (2011). Vital signs: Colorectal cancer screening, incidence, and mortality—United States, 2002-2010. *MMWR Morb Mortal Wkly Rep.* 60:884-889
- Chong A, Shah JN, Levine MS, Ruebesin SE, Laufer I, Ginsberg GG, Long WB, Kochman ML (2002). Diagnostic yield of Barium Enema after incomplete Colonoscopy. *Radiology.* 223: 620-624
- Conteduca V, Sansonno D, Russi S, Dammacco F (2013). Precancerous colorectal lesions (review). *Int J Oncol.* 43(4):973-984.
- Connolly DJA, Trail ZC, Copley SJ, Nolan DJ (2002). The double contrast barium

enema: a retrospective single centre audit of the detection of colorectal carcinomas. *Clin Radiol.* 57:29-32

Dakubo J, Naaeder S, Tettey Y, Gyasi R (2010). Colorectal carcinoma: an update of current trends in Accra. *West Afr J Med.* 29(3): 178-183

De Palma, F.D.E.; D'Argenio, V.; Pol, J.; Kroemer, G.; Maiuri, M.C.; Salvatore, F (2019). The Molecular Hallmarks of the Serrated Pathway in Colorectal Cancer. *Cancers.* 11, 1017. <https://doi.org/10.3390/cancers11071017>

Deschoolmeester V, Baay M, Specenier P, Lardon F, Vermorken JB (2010). A Review of the most Promising Biomarkers in Colorectal Cancer: One step closer to Targeted Therapy. *Oncologist.* 15: 699-731.

Dilley J, Menon U (2014). Tumor markers. In: Smith JR, Priore GD, Coleman RL, Monaghan JM, editor. *An Atlas of Gynaecologic Oncology-Investigation and Surgery.* CRC Press-taylor and Francis Group; 2014. P.1-30

Duffy MJ, Van Dalen A, Haglund C, Hansson L, Holinski-Feder E, Klapdor R, et al. (2007) Tumour markers in Colorectal Cancer: European Group on Tumour Markers (EGTM) guidelines for clinical use. *Eur J Cancer.* 9(43): 1348-60.

Dong Z, Qin C, Zhang Q, Zhang L, Yang H, Zhang J, Wang F (2015). Penile metastasis of sigmoid colon carcinoma: a rare case report. *BMC Urol.* 15: 20

Douaiher J, Ravipati A, Grams B, Chowdhury S, Alatise O Are C (2017). Colorectal cancer-global burden, trends and geographical variations. *J Surg Oncol.* 115(5): 619-630

East JE, Vieth M, Rex DK (2015). Serrated lesions in colorectal cancer screening: detection, resection, pathology and surveillance. *Gut.* 64(6):991-1000

Ebell MH (2018). FIT More Acceptable with better detection rate than Gfobt for Colorectal Cancer Screening. *Clinical Am Fam Physician.* 97(12): 818-20

Frank SA (2007). Dynamics of cancer: Incidence, inheritance, and Evolution. Princeton (NJ): Princeton University Press. Chapter 3, Multistage progression. Retrieved on October 9, 2022 from: <http://www.ncbi.nlm.nih.gov/books/NBK1562/>.

Fyrmpas G, Barbetakis N, Efstathiou A, Konstantinidis I, Tsilikas C (2006). Cutaneous metastasis to the face from colon adenocarcinoma. Case report. *Int Semin Surg Oncol* 3: 2.

Glick S (2000). Double-contrast Barium Enema for Colorectal Cancer Screening: A Review of the issues and a Comparison with other Screening Alternatives. *AJR.* 174: 1529-1537

Globocan. Estimated cancer incidence, mortality and prevalence worldwide 2020. (2020). Retrieved on October 10, 2022 from: [https://gco.iarc.fr/today/data/factsheets/cancers/10\\_8\\_9-Colorectum-fact-sheet.pdf](https://gco.iarc.fr/today/data/factsheets/cancers/10_8_9-Colorectum-fact-sheet.pdf)

Hagggar FA, Boushey RP (2009). Colorectal cancer epidemiology: incidence, mortality, survival and risk factors. *Clinics in colon and rectal surgery.* 22(04); 191 – 197.

Halligan S, Altman DG, Taylor SA et al. (2005). CT Colonography in the detection of colorectal polyps and cancer. Systematic review, meta-analysis, and proposed minimum data set for study level reporting. *Radiology* 237: 893-904

Hemming AW, Davis NL, Kluffinger A (1992). Prognostic markers of colorectal cancer: An evaluation of DNA content, epidermal growth factor receptor, and ki-67. *J Surg Oncol.* 51(3): 88-95

Holowatyl A, Maude AS, Musa HS, Adamu A, Ibrahim S, Abdullahi A, Idoko J,

- Ukwenya Y, Carpten J, Chandler P, Hampel H, Faruk M (2020). Pattern of early-onset colorectal cancer among Nigerians and African Americans. *Global Oncology* 6:1647-1655. <https://ascopubs.org/doi/full/10.1200/GO.20.00272>
- Irabor D, Adedeji O (2009). Colorectal cancer in Nigeria: 40 years on: a review. *European journal of cancer care*. 18(2): 110-115
- Irabor D, Adedeji OA (2009). Colorectal cancer in Nigeria: 40 years on. A review. *European Journal of cancer care*. 18(2): 110 – 115.
- Irabor DO (2011). Colorectal carcinoma: why is there a lower incidence in Nigerians when compared to Caucasians? *J Cancer Epidemiol*. 2011:675154. doi: 10.1155/2011/675154.
- Irabor DO, Afuwape OO, Omobolaji O, Ayandipo (2014), "The Present Status of the Management of Colon and Rectal Cancer in Nigeria". *Journal of Cancer Research*, vol. 2014:1-7. <https://doi.org/10.1155/2014/267190>
- Issa IA, Nouredine M (2017). Colorectal cancer screening: An updated review of the available options. *World J Gastroenterol*. 23(28): 5086-5096
- Kajihara Y, (2019). The apple-core sign of an ileocecal carcinoma, *QJM: An International Journal of Medicine*, Volume 112, Issue 3, Page 229, <https://doi.org/10.1093/qjmed/hcy222>
- Kim MS, Lee J, Sidransky D (2010). DNA methylation markers in colorectal cancer. *Cancer Metastasis Rev*.2010; 29: 181-206
- Krathen RA, Orengo IF, Rosen T (2003). Cutaneous metastasis: A meta-analysis of data. *South Med J*. 96: 164-166.
- Lech G, Slotwinski R, Slodkowski M, Krasnodebski IW. (2016) Colorectal cancer: Global view Colorectal cancer tumour markers and biomarkers: Recent therapeutic advances. *World J Gastroenterol*. 22(5): 1745-55.
- Leslie A, Virjee JP (2002) Detection of Colorectal Carcinoma on Double Contrast Barium Enema when Double Reporting is Routinely Performed: An Audit of Current Practice. *Clin Radiol*. 57:184-7
- Magaji BA, Moy FM, Roslani AC, Law CW. (2017). Survival rates and predictors of survival among colorectal cancer patients in a Malaysian tertiary hospital. *BMC Cancer*. 17(1): 339
- Mead R, Duku M, Bhandari P, Cree IA (2011). Circulating tumour markers can define patients with normal colons, benign polyps, and cancers. *Br J Cancer*. 6: 239-245
- Mensah Y B, Dakubo JCB, Asiamah S and Naaeder SB (2008). Outcome of Barium Enema in Patients with Colorectal Symptoms. *Ghana Medical Journal*. 42: 113-116
- Naaeder S, Archampong E (1994). Cancer of the colon and rectum in Ghana: a 5-year prospective study. *British journal of surgery*. 81(3): 456-459.
- Neri E, Giusti P, Battolla L, Vagli P, Boraschi P, Lencioni R, Caramella D, Bartolozzi C (2002). Colorectal Cancer: Role of CT Colonography in Preoperative Evaluation after Incomplete Colonoscopy. *Radiology*. 223: 615-619.
- Nesseris I, Tsamakis C, Gregoriou S, Ditsos I, Christofidou E, Rigopoulos D (2013). Cutaneous metastasis of colon adenocarcinoma: Case report and review of literature. *An Bras Dermatol*. 88: 56-58.
- Newton KF, Newman W, Hill J (2012). Review of biomarkers in colorectal cancer. *Colorectal Dis*. 14(1):3-17. doi: 10.1111/j.1463-1318.2010.02439.x.
- Orugbo VP, Akpo EE (2021). Metabolic changes in colorectal carcinomas are key factors for the early detection of neoplastic

change. *Annals of Clinical and Biomedical Research* 2:55-62

Patnayak R, Mishra S, Jena A (2008). Cutaneous metastases from colon carcinoma – An unusual presentation. *J Med Oncol Ther.* 3(2): 34-35

Poullis A, Foster R, Shetty A, Fagerhol MK, Mendall MA (2004). Bowel inflammation as measured by fecal calprotectin: a link between lifestyle factors and colorectal cancer risk. *Cancer Epidemiol Biomarkers Prev.* 13(2):279-84. doi: 10.1158/1055-9965.

Rahman G (2010). Rectal cancer. Pattern and outcome of management in University of Ilorin teaching hospital, Ilorin, Nigeria. *Ann Afr Med.* 9(3):164-169

Rex DK. Considering Double Contrast Barium Enema and its Demise: A case for Systematic Video recording of Colonoscopy (2008). *Am J Gastroenterol.* 103: 3149-51

Shariff MK, Sheikh K, Carroll NR, Whitley S, Greenberg D, Parkes M, Cameron EAB (2011). Colorectal cancer detection: time to abandon barium enema? *Frontline Gastroenterol.* 2: 105-109.

Sheets N, Powers J, Richmond B (2014). Cutaneous metastasis of colon cancer: case report and literature review. *W V Med J.* 110: 22-24.

Siegel R, Ward E, Brawley O, Jemal A. Siegel R, Ward E, Brawley O, Jemal A (2011). Cancer statistics, 2011: the impact of eliminating socioeconomic and racial disparities on premature cancer deaths. *CA Cancer J Clin.* 61(4):212-36. doi: 10.3322/caac.20121. Epub 2011 Jun 17. PMID: 21685461.

Simon K (2016). Colorectal cancer development and advances in screening. *Clin Interv Aging.* 11:967-976.

Simon K, Balchen V (2016). Colorectal cancer development and advances in screening. *Clin Interv Aging.* 11: 967-976

Snover DC (2011). Update on the serrated pathway to colorectal carcinoma. *Human Pathol.* 42(1):1-10. <https://doi.org/10.1016/j.humpath.2010.06.002>.

Stracci F, Zorzi M, Grazzini G (2014). Colorectal cancer screening: tests, strategies, and perspectives. *Front Public Health.* 27(2):210. doi: 10.3389/fpubh.2014.00210.

Tanaka T, Tanaka M, Tanaka T, Ishigamori R (2010). Biomarkers for Colorectal Cancers. *Int J Mol Sci.* 11: 3209-25

Tan KY, Seow-Choen F, Ng C, Eu KW, Tang CL, Heah SM (2004). Which Colorectal Cancers are missed by Double Contrast Barium Enema? *Tech Coloproctol.* 8: 169-72

Thanikachalam K, Khan G (2019). Colorectal cancer and Nutrition. *Nutrients.* 11(1): 164

Theyra-Enias H, Adewuyi SA, Alabi A, Jummai DJ, Zubairu IH (2020). Socio-demographic and clinico-pathologic pattern of patients with colorectal cancers seen in Ahmadu Bello University Teaching Hospital, Zaria. *West African Journal of Radiology.* 2(27):136-142

Toma J, Paszat LF, Gunraj N, Rabeneck L (2008). Rates of New or Missed Colorectal Cancer after Barium Enema and their risk factors: A population-based study. *Am J Gastroenterol.* 103: 3142-3148

Wang DY, YE F, Lin JJ, Xu X (2017). Cutaneous metastasis: A rare phenomenon of colorectal cancer. *Ann Surg Treat Res.* 93: 277-280

Xie, YH., Chen, YX. & Fang, JY (2020). Comprehensive review of targeted therapy for colorectal cancer. *Sig Transduct Target Ther.* 5, 22. <https://doi.org/10.1038/s41392-020-0116-z>.

Yamane L, Scapulatempo-Neto C, Reis RM, Guimaraes DP (2014). Serrated

pathway in colorectal carcinogenesis. *World J Gastroenterol.* 20(10):2634-2640

Yang H, Xia B, Jiang B, Wang G, Yang Y (2013). Diagnostic value of stool DNA testing for multiple markers of colorectal cancer and advanced adenoma: *Can J. Gastroenterol.* 27(8): 467-76

Yee J, Akerkar GA, Hung RK, Steinauer-Gebauer AM, Wall SD, Mc Quaid RM (2001). Colorectal Neoplasia: Performance Characteristics of CT Colonography for Detection in 300 patients. *Radiology.* 219: 685-692

Zanwar VG, Pawar SV, Jian SS, Nayak CS, Rathi PM (2016). Cutaneous lesions in colorectal carcinoma: A rare presentation. *Intest Res.* 14:102-103